January 2016| Issue 1

Use of MENTOR® ARTOURA™

Breast Tissue Expander in Delayed Reconstruction

Salvatore J. Pacella, M.D., M.B.A, F.A.C.S.
Division Head, Plastic & Reconstructive Surgery
Scripps Clinic & Green Hospital
La Jolla, California

Delayed Breast Reconstruction presents numerous challenges in creating an aesthetic breast appearance. Ablation of the inframammary fold and breast pocket distortion must be managed appropriately to maintain a viable tissue envelope in preparation for implant exchange. In this paper, we examine the utility of an engineered, directional tissue expander that can prove effective in these scenarios.

INTRODUCTION:

Over the last twenty years, there has been a significant paradigm shift in breast reconstruction toward immediate reconstruction after mastectomy.[1] This change provides significant benefits to the patient by avoiding a delayed interval in which patients must live with potentially deforming breast scars and the loss of projection of a natural breast. In addition, immediate reconstruction provides the surgeon an opportunity to control the thickness of the mastectomy flap as well as providing three dimensional architecture to control the mastectomy skin pocket.

Although it may be preferential to provide an immediate tissue expander or implant-based reconstruction, these options are not feasible in every scenario. Patients who are elderly, patients who smoke, and those who have significant co-morbidities such as diabetes, heart disease or autoimmune disease may not be ideal candidates. In these populations, placement of a tissue expander or prosthesis in an immediate fashion may carry a high risk of surgical site infection resulting in the loss of the tissue expander. Thus, delayed tissue expander breast reconstruction may be preferable in these circumstances. Tissue expansion in this setting presents some inherent challenges in providing an aesthetic breast shape. After the mastectomy skin flap has healed to the chest wall, the defined anatomic attachments of the inframammary fold have often been ablated. When tissue expansion is attempted in this setting, the inframammary fold often appears high, blunted and poorly defined. Traditional tissue expanders, which may deform under pressure from muscle or ADM pressure vectors, oftentimes do not adequately maintain the natural depression in the inframammary fold.[2] In addition, patients who have aggressive cancers that may require post-operative radiotherapy will often have very limited flexibility in skin distention. In these scenarios, many authors have advocated the use of autologous tissue alone (i.e. DIEP, TRAM flaps) or muscle flaps (i.e. latissimus dorsi flap) with the use of an expander device.[3,4] Reconstruction with these modalities can often result in higher morbidity, longer post-operative recovery and increased health system cost.[5,6] Though immediate or delayed tissue expansion may be pursued, muscle pressure, ADM distortion, expander shifting or radiation may result in loss of pocket control. In situations where direct-to-implant reconstruction is chosen, interval adjustment of the breast pocket is often not feasible, particularly if unexpected postoperative radiation is required. In secondary scenarios where tissue expansion results in a distorted pocket, surgeons may opt to continue expansion in an attempt to maintain the dimensions of the mastectomy pocket. It may be seen as retrograde progress to decide on secondary or revisional delayed tissue expansion (i.e. "starting from scratch") as opposed to continuing forward with implant exchange and attempting surgical pocket manipulation in the under-expanded pocket. In the following cases, we examine the utility of the ARTOURA Expander in creation of a natural and ptotic breast pocket, both in delayed reconstruction and in secondary/revisional delayed reconstruction.

CASE STUDIES:

Case #1 Use of MENTOR® ARTOURA™ Breast Tissue Expander in Delayed Reconstruction with Destruction of Inframammary Fold

This 68 year old female was diagnosed with left sided invasive breast cancer. She opted for left mastectomy without immediate reconstruction. Several months after the mastectomy, she desired to undergo delayed breast reconstruction. On initial examination, the ablative nature of the mastectomy has resulted in a skin flap with irregular thickness and contour deformity, as well as axillary notching (Fig 1 A, B, C). In addition, adherence to the chest wall and destruction of the dermal attachments of the inframammary fold have resulted in "reverse projection" or an "indentation" of the breast scar (Fig 1 D, E).

In an effort to facilitate delayed expansion, a 650 cc Ultra High Profile ARTOURA Expander was utilized. Superiorly, the expander was placed in the submuscular position after elevation and release of the tangential attachments of the inferior border of the pectoralis muscle. On the table prior to closure, the tissue expander was initially filled to an initial volume of 140 cc.

The patient required 5 fills with approximately 100 cc expansion volumes. The design of the dimensional component of the ARTOURA Expander resulted in excellent lower pole breast expansion with minimal upper pole distortion. Furthermore, the use of quilting sutures resulted in redefinition of a natural appearing inframammary fold. In addition, the design of ARTOURA Expander's focal band and lateral anchor resulted in appropriate re-contouring of the left sided axillary notching deformity (Fig 2 A-E).

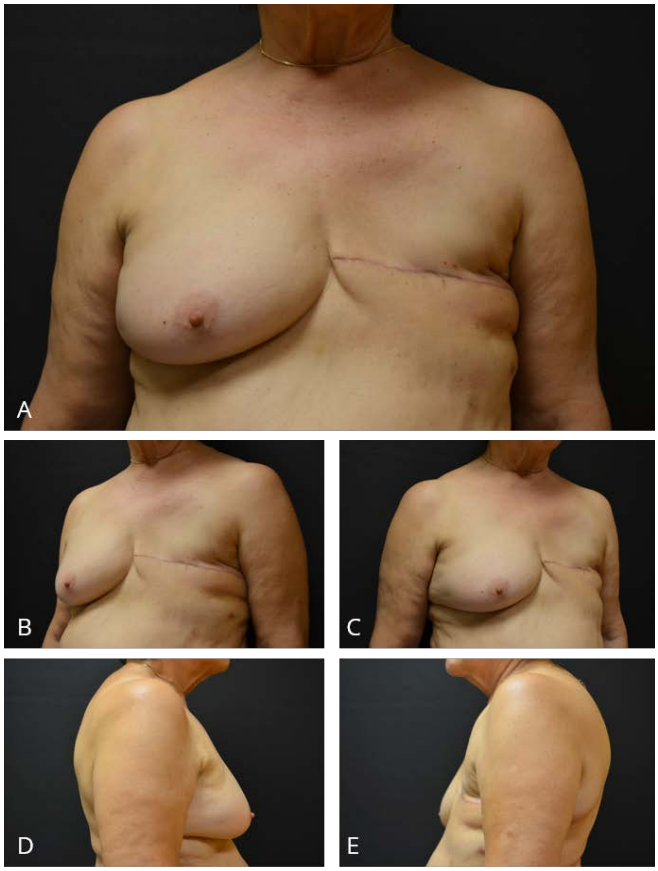

FIGURE 1

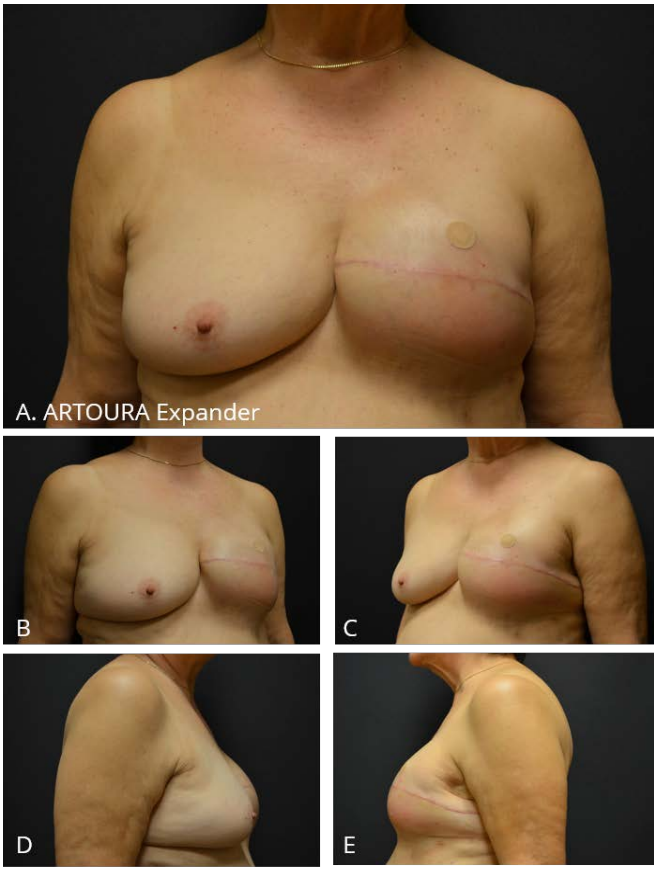

FIGURE 2

Case #2: Use of MENTOR® ARTOURA™ Breast Tissue Expander in Secondary Delayed Reconstruction After Distortion of Breast Pocket

This 58 year old patient was referred several months after undergoing delayed reconstruction following left sided mastectomy. Her operative record from an outside hospital described a complete submuscular reconstruction that was performed through the pectoralis muscle. According to the operative note, the lower muscle flap was elevated en bloc with the lower attachments of the pectoralis and serratus muscles. A standard moderate profile MENTOR® CPX®4 Breast Tissue Expander was utilized and filled to 120 cc.

Her care was transferred, and after several rounds of expansion to a volume of 320 cc, the patient complained of excessive muscle tightness and spasms, resulting in excessive pain with arm movement. On initial and subsequent examinations following interval expansion, the breast pocket appeared very high, resulting in significant pocket distortion and shortening of the distance of the scar to the inframammary fold (Fig 3 A- E). After a discussion of potential alternative options to salvage her reconstruction, she opted for secondary delayed reconstruction with expander replacement and pocket revision.

FIGURE 3

Intraoperatively, the breast pocket was entered by dividing the attachments of the pectoralis from the serratus border (Fig 4 A and Fig 4 B illustration). Her tissue expander was removed and the lower border of the pocket appeared significantly constricted and under-dissected. The lower attachments of the pectoralis muscle were divided completely and the serratus was reattached back to its native chest wall position with 3-0 Vicryl sutures. (Fig 4 C and Fig 4 D illustration). A 600 cc High Profile ARTOURA Expander was placed in the subpectoral space. Initial fill volume was 300 cc.

Figure 5 A- E illustrates the appearance of the final fill of the ARTOURA Expander to 520 cc after several interval expansions. Postoperatively, the distance of the scar to the inframammary fold was greatly increased, was in the lower

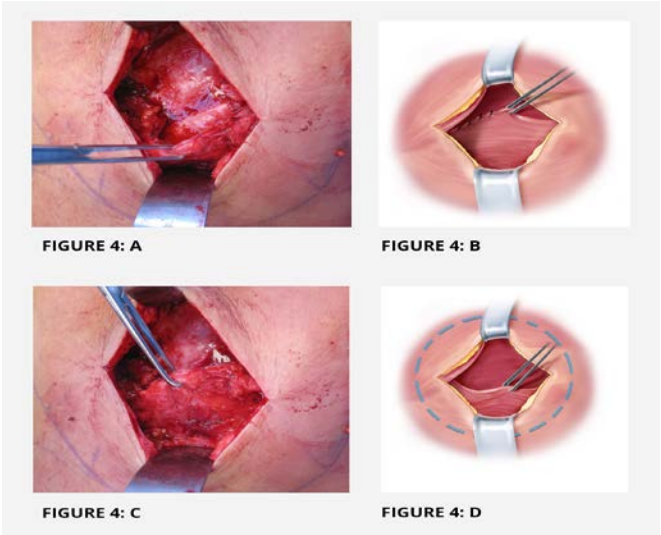

pole projection. During this secondary reconstruction, the overexpansion of the superior pole of the breast was significantly limited by ARTOURA Expander's superior rein.

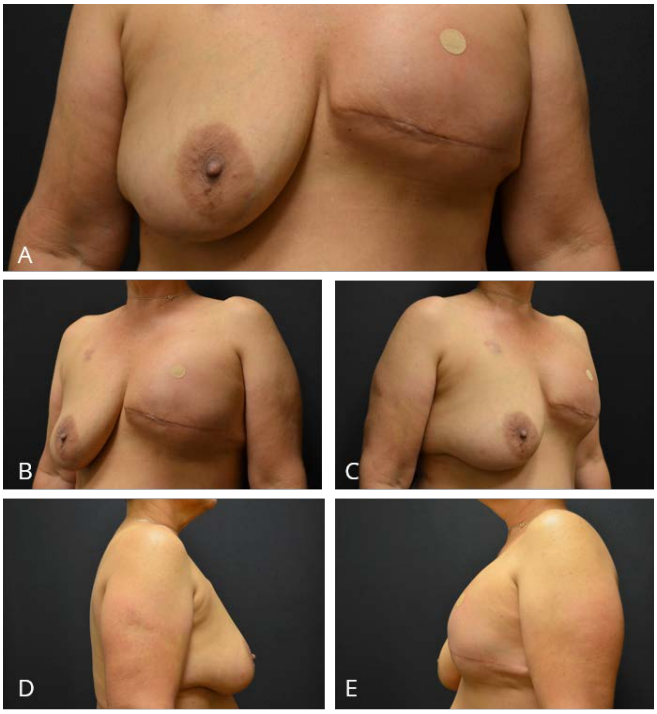

FIGURE 5

CONCLUSION:

The unique design of the MENTOR® ARTOURA™ Breast Tissue Expander can be useful in reducing the distortion of the inframammary fold position and in the reshaping of the breast pocket in preparation for final implant exchange. The superior rein can be effective in over-exploitation of the superior pole, which may be caused by a tight submuscular pocket or serratus constriction. The focal band design can provide excellent lower pole directional expansion to reshape the natural ptosis desired in breast reconstruction. The design of the lateral band can limit lateral expansion and provide a firm construct to address the unaesthetic appearance of an axillary notching deformity seen superior-laterally following aggressive mastectomies.

Strategic planning in preparation for correction of these deformities in delayed reconstruction can result in excellent aesthetic shape in preparation for secondary stage implant exchange.

ARTOURA Expander

1 Basta, Marten N.; Gerety, Patrick A.; Serletti, Joseph M. A Systematic Review and Head-to-Head Meta-Analysis of Outcomes following Direct-to-Implant versus Conventional Two-Stage Implant Reconstruction
Plastic & Reconstructive Surgery. 136(6):1135-1144, December 2015
2 Spear, Scott L.; Sher, Sarah R.; Al-Attar, Ali; Applications of Acellular Dermal Matrix in Revision Breast Reconstruction Surgery Plastic & Reconstructive Surgery. 133(1):1-10, January 2014
3 Knox AD, Ho AL, Leung L, Tashakkor AY, Lennox PA, Van Laeken N, Macadam SA.
Comparison of Outcomes Following Autologous Breast Reconstruction using the DIEP and Pedicled TRAM Flap Part 1: A 12 Year Clinical Retrospective Study and Literature Review.
Plast Reconstr Surg. 2015 Epub
4 Pacella SJ, Vogel JE, Locke MB, Codner MA. Aesthetic and technical refinements in latissimus dorsi implant breast reconstruction: a 15-year experience. Aesthet Surg J. 2011 Feb;31(2):190-9
5 Fitzpatrick, Aisling M.; Gao, Lin Lin; Smith, Barbara L.; Cost and Outcome Analysis of Breast Reconstruction Paradigm Shift Plastic & Reconstructive Surgery. 130(5S-1):75, November 2012
6 Spear, Scott L.; Mardini, Samir; Ganz, Jason C. Resource Cost Comparison of Implant-Based Breast Reconstruction versus TRAM Flap Breast Reconstruction Plastic & Reconstructive Surgery. 112(1):101-105, July 2003

This white paper includes a demonstration of the use of a surgical device; it is not intended to be used as a surgical training guide. Other surgeons may employ different techniques. The steps demonstrated may not be the complete steps of the procedure. Individual surgeon preference and experience, as well as patient needs, may dictate variation in procedure steps. Before using any medical device, including those demonstrated or referenced in this white paper, review all relevant package inserts, with particular attention to the indications, contraindications, warnings and precautions, and steps for use of the device.

Important Safety Information:
The ARTOURATM Breast Tissue Expander or CONTOUR PROFILE® Breast Tissue Expander can be utilized for breast reconstruction after mastectomy, correction of an underdeveloped breast, scar revision, and tissue defect procedures. The expander is intended for temporary subcutaneous or submuscular implantation and is not intended for use beyond six months. Do not use the ARTOURATM Tissue Expander nor CONTOUR PROFILE® Tissue Expander in patients where an MRI may be needed. The device could be moved by the MRI causing pain or displacement, potentially resulting in a revision surgery. The incidence of extrusion of the expander has been shown to increase when the expander has been placed in injured areas.

For detailed indications, contraindications, warnings, and precautions associated with the use of all MENTOR® Implantable Devices, which include MENTOR® Saline-filled Implants, MemoryGel® Implants, MemoryShape® Implants, ARTOURA™ Expanders, and CONTOUR PROFILE® Expanders, please refer to the Product Insert Data Sheet provided with each product or visit www.mentorwwllc.com.